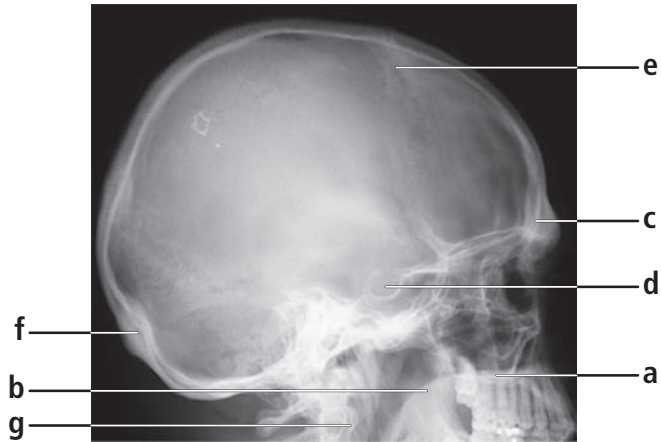
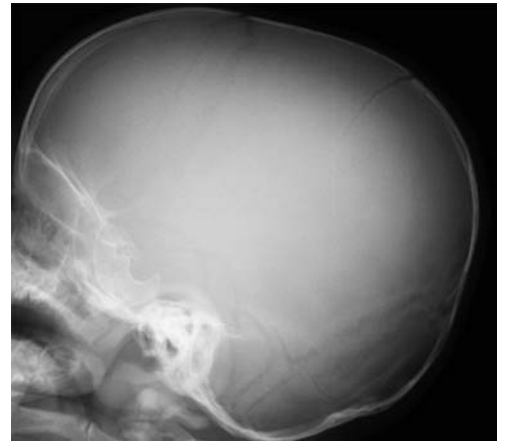
1a. Name these structures



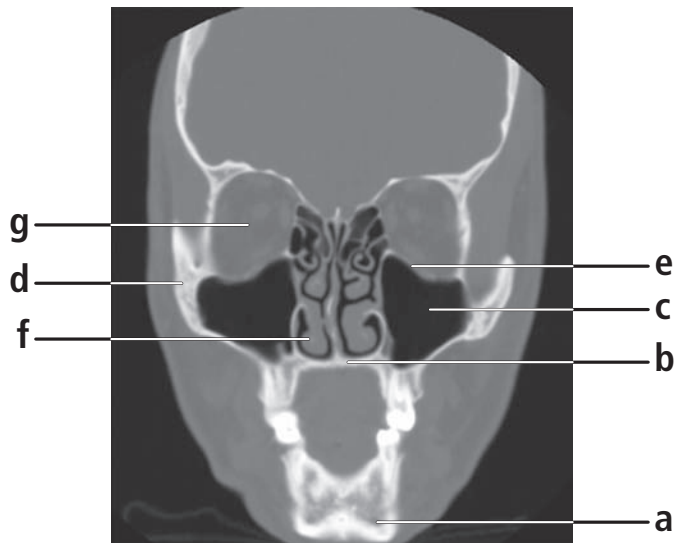
1b. What is your diagnosis?

## Answers 1a.

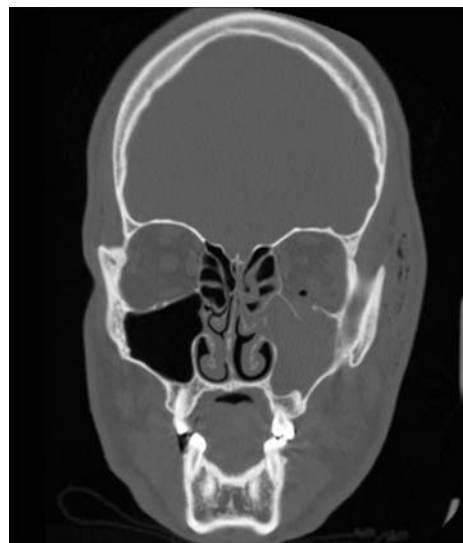
- a. hard palate
- b. soft palate
- c. frontal sinus
- d. sella turcica
- e. coronal suture
- f. external occipital protuberance
- g. anterior arch of C1

## Answer 1b.

Linear parietal skull fracture  
*(note: sharp radiolucent line without branching)*



2a. Name these structures



2b. What is your diagnosis?

## Answers 2a

- a. Mandible
- b. alveolar ridge
- c. maxillary sinus
- d. zygoma
- e. orbital floor
- f. inferior turbinate
- g. optic nerve

## Answer 2b.

Blowout fracture left orbit

*(note: air in left orbit and air in subcutaneous tissue)*